



Does labral treatment technique influence the outcome of FAI surgery? A matched-pair study of labral reconstruction versus repair and debridement with a follow-up of 10 years

Pierre Laboudie ^{1,2}, Paul Gauthier^{1,2}, Cheryl Kreviazuk^{1,3} and Paul E. Beaulé ^{1,2,3*}

¹Division of Orthopedic Surgery, The Ottawa Hospital (TOH), 501 Smyth Road, Ottawa, ON K1H 8L6, Canada, ²Faculty of Medicine, The University of Ottawa, Roger Guindon Hall, 451 Smyth Rd #2044, Ottawa, ON K1H 8M5, Canada and ³Clinical Epidemiology Program, The Ottawa Hospital Research Institute, 501 Smyth Road, Ottawa, ON K1H 8L6, Canada.

*Correspondence to: P. E. Beaulé. E-mail: pbeaule@toh.ca

ABSTRACT

The aim of this study was to analyze the long-term clinical outcomes of labral reconstruction in patients undergoing femoro-acetabular impingement (FAI) surgery and compare them with labral repair and debridement. This is a single-center, single-surgeon, retrospective match-paired study from a prospectively collected hip preservation database. All patients underwent a hip surgical dislocation for FAI surgery. Eight patients underwent labral reconstruction with the ligamentum teres and were matched on sex, age and body mass index with 24 labral repair and 24 labral debridement (1:3). Failure was defined as conversion to total hip replacement (THR) and patient-reported outcome measures (PROMs) were collected. Mean follow-up was 9.8 years \pm 2.6 (5.2–13.9). There was a significant improvement in postoperative PROMs in the three groups regarding the WOMAC total, WOMAC function, HOOS-QoL, HOOS-ADL and HOOS-SRA ($P < 0.05$). There was no statistical difference between the three groups regarding postoperative PROMs and change in PROMs ($P > 0.05$). A total of 10 hips underwent joint replacement surgery at a mean time of 7.9 \pm 3.5 years (2.4–12). There was no statistically significant difference between the three groups regarding the conversion rate to THR ($P = 0.64$) or time between surgery and conversion to THR ($P = 0.15$). Compared to a match-pair group of labral repair and debridement, labral reconstruction with ligamentum teres provides similar survival with conversion to a THR as an endpoint, as well as similar improvement in PROMs. Labral treatment can be safely adapted at the nature of the labral lesion with a treatment ‘à la carte’.

INTRODUCTION

Surgical management of femoro-acetabular impingement (FAI) has evolved tremendously in the last two decades in terms of surgical techniques, indications and management of the labrum. Early on, the damaged labrum was often resected to the bony rim; however, it was quickly realized [1–3] that preservation either by means of partial debridement or re-stabilization with anchors gave superior results [4, 5]. In addition, when the labrum was extensively damaged or calcified, techniques of complete labral reconstruction, such as using the ligamentum teres or iliotibial band graft, were developed with promising early results [6–8]. These techniques were initially performed through open surgery and are now mostly performed with arthroscopy; however, in our opinion, there are still indications for open surgery for the treatment of FAI (large cam extending posteriorly, acetabular global overcoverage and complex childhood deformities). Both *in vitro* biomechanical studies [1, 2, 9, 10] and clinical studies have shown the benefits of preserving the labrum [7, 11] or reconstructing its seal effect; however, most of the clinical studies are short term [12–15]. The acetabular labrum plays a critical role in

enhancing hip stability [10, 16, 17], maintaining cartilage health [2, 18] and decreasing cartilage strain [3, 9, 17]. Its triangular shape made of fibrocartilage creates a seal effect due to its circumferential tensile properties [1], permitting the creation of an intra-articular negative pressure. As the extent of labral damage depends on the severity of bony deformity and duration of symptoms, it is critical to determine how various surgical techniques for labral management will affect long-term function and joint survivorship. The purpose of this study was to report long-term and patient-reported outcomes measures (PROMs) at 10 years after a labral reconstruction with ligamentum teres compared to both repair and debridement, all performed through an open hip surgical dislocation.

METHOD

Patient selection criteria

After the institutional review board, data from our prospective collected hip preservation database were retrospectively reviewed for all patients undergoing FAI treatment surgery

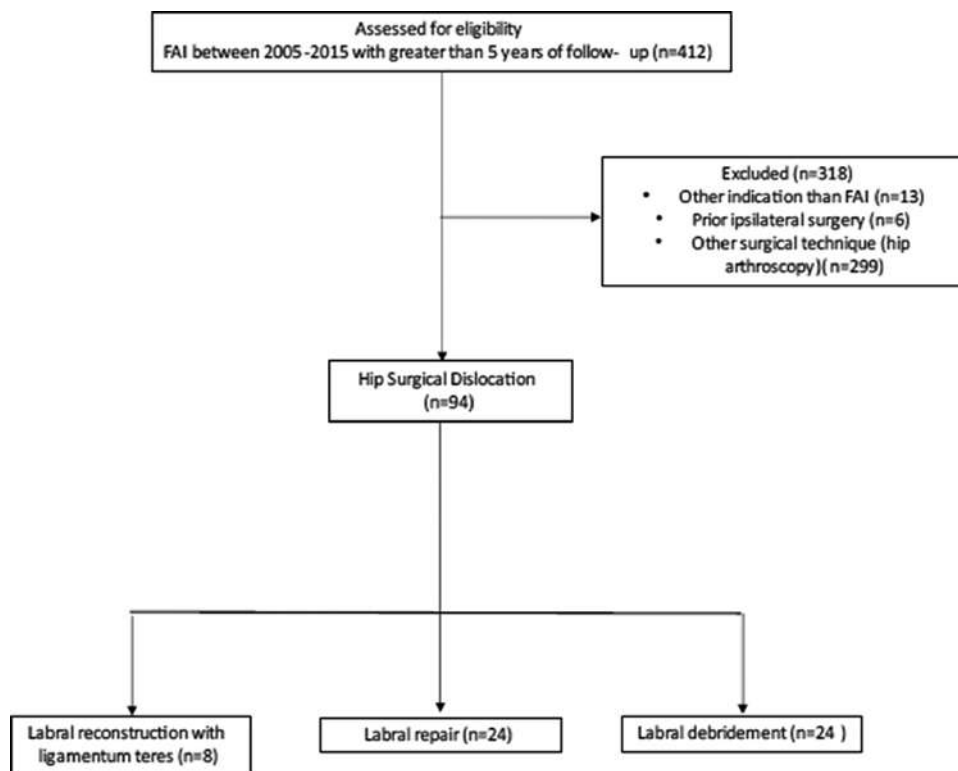


Fig. 1. Flow chart of the patients through the study.

during 2005 and 2015 by the senior author. The flow chart of the patients is detailed in Fig. 1.

Inclusion criteria were: undergoing a hip surgical dislocation for primary FAI and having a segmental labral reconstruction with the ligamentum teres (group 1) with a minimal follow-up of 5 years.

Exclusion criteria were: prior ipsilateral hip surgery, concomitant procedure [i.e. periacetabular osteotomy (PAO)] and indications other than FAI [childhood deformities, dysplasia diagnosed by a lateral center edge angle (LCEA) below 25°].

Matching process

Patients undergoing labral reconstruction were matched on two control groups undergoing either labral repair or labral debridement. The match was based on gender, age ± 5 years and body mass index (BMI) ± 5 kg/m². In order to increase the power, each labral reconstruction was matched with three labral repair and three labral debridement (1:3).

A total of eight hips satisfied the inclusion criteria for the labral reconstruction group and were matched with 24 hips undergoing labral repair (Group 2) and 24 hips undergoing labral debridement (Group 3). Demographic and radiographic data are provided in Table I. LCEA was measured to the sclerotic lateral sourcil edge [19], and the end joint space was measured at the narrowest point of the joint.

Indication for surgery

All patients were under the care of a single surgeon and had failed nonoperative treatment for at least 6 months. The morphological

type associated with FAI was classified by the lead surgeon using established criteria [20] at the time of surgery and divided into three groups: cam, pincer or mixed. A cam lesion was defined using previously defined criteria (alpha angle $>55^\circ$ on the 45° Dunn view) [21], a pincer was defined by either a global overcoverage with LCEA greater than 35° or an isolated acetabular retroversion with crossover sign (extending >10 mm from acetabular roof) but normal LCEA [20] and a mixed FAI was defined by a combination of a cam and a pincer lesion.

Surgical technique and rehabilitation

All patients underwent a hip surgical dislocation as described by Ganz *et al.* [22]. After the hip was dislocated, ligamentum teres was excised using a surgical knife and conserved for possible labral reconstruction.

Routine FAI bony correction was executed, the femoral osteochondroplasty (FOCP) was performed after the use of head size template in order to obtain a satisfactory anterior head–neck offset with a concavity at the head–neck junction. Acetabular rim trimming was performed with osteotome and burr in order to remove the pincer deformity.

Decision to reconstruct or repair the labrum was made by the surgeon intraoperatively. Patients were considered for labral repair in presence of a labral tear or unstable labrum and enough viable labral tissue or for labral debridement in presence of labral fibrillation without detachment of the labrum from the acetabular rim.

Patients were considered for labral reconstruction if a segmental defect or a nonviable labral tissue such as labral ossification

Table I. Demographic data of the three surgical groups

Parameter	Labral reconstruction (8 hips)	Labral repair (24 hips)	Labral debridement (24 hips)	P-value
Age/years	27.9 ± 9.1	28 ± 7.9	32.2 ± 7.3	0.147
Male sex	8 (100%)	24 (100%)	24 (100%)	/
BMI (kg/m ²)	27 ± 6.7	25.2 ± 4.6	27.2 ± 4.1	0.401
Follow-up (years)	8.3 ± 2.6	11.9 ± 2.1	11.9 ± 1.7	0.07
Radiographic findings				
LCEA ^o	46.4 ± 11.7	40.3 ± 6.4	42 ± 1.4	0.222
Alpha angle ^o	57.2 ± 7.6	65.1 ± 15	70 ± 10.6	0.071
End joint space (mm)	3.2 ± 1.4	5.2 ± 4.6	4.1 ± 1.3	0.282
Tönnis OA grade [23]				
0	3 (37.5%)	10 (42%)	4 (16%)	0.244
1	2 (25%)	10 (42%)	4 (16%)	
2	3 (37.5%)	4 (16%)	10 (42%)	

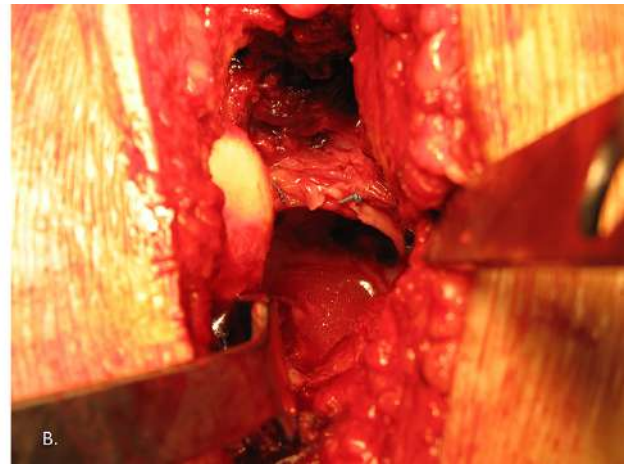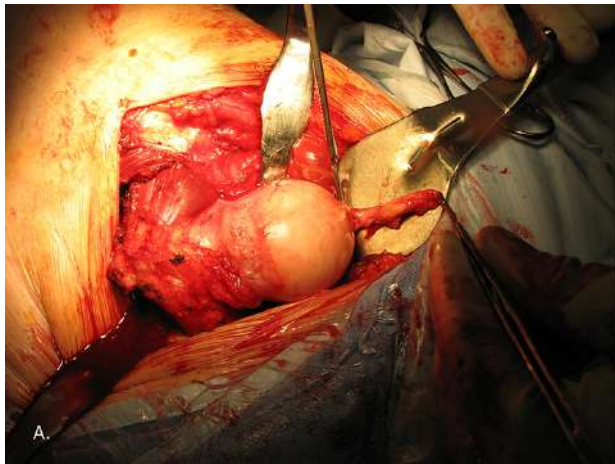


Fig. 2. (A) Ligamentum teres attached to the femoral head after hip dislocation. (B) The ligament has been divided lengthwise and sutured to the rim with anchors, realizing a segmental labral reconstruction.

were found during surgery and had deficient length of more than 3 mm in order to provide the room for at least two suture anchors.

Once the decision to reconstruct the labrum was made, irreparable labral tissue was debrided, acetabular rim trimming was performed in order to have good bleeding bone. Labral reconstruction using the ligamentum teres was performed according to a previously published technique [24]. But, in brief, the ligament was divided lengthwise to obtain a suitable length to cover the defect. It was then positioned on the acetabular rim and secured with several anchors (one per centimeter). Additional sutures were made to secure the graft to the adjacent native labrum (Fig. 2).

Our postoperative protocol included partial weight bearing and abduction limitation for 6 weeks to protect the trochanteric osteotomy.

Clinical outcome

Length of outcome was determined from the last clinical encountered. Cartilage status was documented using the Beck Grade [25], and PROMs were collected: SF-12 [26], WOMAC [27], HOOS [28] and the UCLA activity score [29]. Preoperative radiographic measurements were assessed by a hip preservation

fellow. The Tönnis classification [30] was used to determine the osteoarthritic status, as well as the end joint space.

Statistical analysis

Data were summarized using descriptive statistics, including count and percentages for categorical variables. Continuous variables were described using the mean and standard deviation (SD), and categorical variables were presented with total count and percentages. The chi-squared and Fisher's exact tests were used to test for differences between categorical variables, and the Mann-Whitney U test was used for continuous variables. All analyses were performed using IBM SPSS (Statistical Product and Service Solutions) software for Mac 9 (version 27).

RESULTS

Intraoperative findings

In the labral reconstruction group, there were four hips (50%) with a chondral damage ≥ 4 according to Beck; seven hips (88%) underwent FOCP and six hips (75%) underwent rim trimming. There was no difference between the three groups except the incidence of hips undergoing rim trimming ($P < 0.001$). This is demonstrated in Table II.

Table II. Intraoperative findings and procedures of the three surgical groups

Parameter	Labral reconstruction (8 hips)	Labral repair (24 hips)	Labral debridement (24 hips)	P-value
Acetabular cartilage damage (Beck)				0.103
1. Normal	4 (50%)	10 (42%)	3 (12%)	
2. Malacia	0	0	1 (4%)	
3. Debonding	0	1 (4%)	2 (8%)	
4. Cleavage	2 (25%)	11 (46%)	7 (29%)	
5. Defect	2 (25%)	1 (4%)	8 (33%)	
Surgical procedure				
FOCP	7 (88%)	24 (100%)	24 (100%)	0.05
Rim trimming	6 (75%)	21 (88%)	0 (0%)	<0.001
Microfracture	0 (0%)	4 (17%)	10 (42%)	0.02

Patient-reported outcome measures

Complete preoperative and postoperative PROMs were completed for 73% of the patients, 7 in Group 1, 15 in Group 2 and 19 in Group 3 ($P = 0.32$). There was a significant improvement in postoperative PROMs in the three groups regarding the WOMAC total, WOMAC function, HOOS-QoL, HOOS-ADL and HOOS-SRA ($P < 0.05$). There was no statistical difference between the three groups regarding postoperative PROMs and change in PROMs ($P > 0.05$) as confirmed in Table III.

Reoperations and conversion to hip replacement

A total of 10 hips underwent joint replacement surgery at a mean time of 7.9 ± 3.5 years (2.4–12). There was no statistically significant difference between the three groups regarding the conversion rate to total hip replacement (THR; $P = 0.64$), as well as time between surgery and conversion to THR ($P = 0.15$), as established in Table IV.

DISCUSSION

The main result of our study is that labral reconstruction with the ligamentum teres gives satisfactory outcomes after an average follow-up of 10 years. Hip preservation surgery is relatively a new field within orthopedic surgery as such indications and techniques have evolved tremendously, which always poses a challenge in regard to achieving the highest level of quality of care. The underlying principles are to correct the bony abnormality in order to restore the hip kinematics, thus avoiding further joint deterioration [31]. Having said that, how one manages the labrum has been recognized as an important determinant of clinical outcome as well [32, 33]. In our study, we found comparable long-term results with similar improvement of the PROMs, as well as an equal rate of conversion to a THR between three types of labral treatment.

To our knowledge, this is the first study to report long-term results of labral reconstruction with the ligamentum teres. After the technique was initially described by Sierra *et al.* [24], short-term results were reported by the same team through Walker *et al.* [8]. They reported after a minimum follow-up of 1 year the results of 20 labral reconstructions and found improvement in pain and function for 15 patients, with 3 patients being converted to a THR. It was also interesting to see that a patient undergoing a hip arthroscopy after the reconstruction had a healed,

viable labral graft with restitution of an optimal suction seal. Camenzind *et al.* [34] also reported a significant improvement in PROMs after a mean follow-up of 38 months, with similar improvements compared to a group of labral repair.

In our department, when we perform an open hip surgical dislocation, we continue to use the ligamentum teres as a graft for labral reconstruction even though it presents some limitations such as limited length, difficulty to control the width of the graft and a graft not as robust as a fascia. Many other transplant options are now available [6], and satisfactory short-term outcomes have been reported for rectus femoris autograft [35], iliotibial band auto [36] and allo-graft [14, 15]; gracilis tendon autograft [13] and anterior tibialis tendon allograft [37] Philippon *et al.* [36] reported long-term results of labral reconstruction using an iliotibial band autograft through an arthroscopic approach on 82 hips. After a minimum follow-up of 10 years, they found that the survivorship was 61% at 10 years. For the patients who did not undergo subsequent surgery, they found a significant improvement in mHHS, HOOS-ADL and HOOS-SRA with the median patient satisfaction at 10 of 10. Our results appear to be quite comparable to those from this study and show that an adapted treatment of the labrum whatever the surgical technique (arthroscopy versus surgical dislocation) allows obtaining satisfactory long-term results.

In our study, we observed an improvement of the majority the PROMs in the three groups: labral reconstruction, labral repair and labral debridement. We did not find any significant difference in the groups in term of hip joint survival nor subjective outcomes. With the knowledge that our decision for the labral treatment used was based on the length of the labral tear as well as the stability and the state (i.e ossified or not) of the labrum, it is therefore reassuring that with this algorithm, optimal outcomes can be achieved, and labral treatment 'à la carte' can be safely used; after a long-term evaluation (10 years).

All three treatments have been widely studied and compared in the literature. Maldonado *et al.* [7] compared the outcomes of 38 labral reconstructions with 38 labral segmental resections at a minimum follow-up of 2 years. They report that the conversion rate to THR was significantly lower with labral reconstruction (5.3%) versus resection (21.1%). Schilders *et al.* [38] compared the arthroscopic labral repair to labral resection at a minimum follow-up of 2 years and reported that the postoperative mHHS in the labral repair group was 7.3 points greater than in the labral

Table III. Preoperative and postoperative PROMs for the three surgical groups

PROMs	Labral reconstruction (8 hips)	Labral repair (24 hips)	Labral debridement (24 hips)	P-value (inter-groups)
WOMAC pain				
Pre	9 ± 3.9	11.8 ± 3.3	8.9 ± 4.3	0.13
Post	4.4 ± 4.2	2.2 ± 3.1	5.1 ± 3.7	0.07
Change	3.4 ± 4.3	3.5 ± 2.1	3.3 ± 2.9	0.1
P-value (pre-post)	0.14	0.01	0.06	
WOMAC stiffness				
Pre	4.9 ± 1.6	3.3 ± 1.4	4.3 ± 1.3	0.07
Post	3 ± 2.1	2.2 ± 1.5	3.6 ± 2.6	0.16
Change	1.3 ± 2.1	0.9 ± 1.1	0.7 ± 2.3	0.8
P-value (pre-post)	0.13	0.07	0.68	
WOMAC function				
Pre	30 ± 11	15 ± 11	28.9 ± 15	0.015
Post	13.2 ± 10.3	8.6 ± 8.9	16.2 ± 14.7	0.2
Change	13.5 ± 10	8.1 ± 7.8	11.8 ± 13.1	0.63
P-value (pre-post)	0.03	0.03	0.03	
WOMAC total				
Pre	43.7 ± 13.6	24.6 ± 14.8	46 ± 17.4	0.011
Post	21.8 ± 16.5	12.8 ± 12.8	25 ± 20.2	0.13
Change	14.8 ± 11.9	12.8 ± 8.5	18.5 ± 17.3	0.72
P-value (pre-post)	0.04	0.01	0.04	
SF-12 mental				
Pre	42.8 ± 12	53.2 ± 5	49.9 ± 17	0.179
Post	41.5 ± 13.4	56 ± 5.3	45.3 ± 15.7	0.21
Change	0.8 ± 13.3	2.1 ± 8	-1.6 ± 12.4	0.754
P-value (pre-post)	0.75	0.5	0.38	
SF-12 physical				
Pre	36.1 ± 8	43 ± 7	39.2 ± 7.3	0.106
Post	42.7 ± 7.4	49 ± 6.9	45.4 ± 10.6	0.32
Change	4.5 ± 11	7.6 ± 9.6	5.2 ± 10.9	0.811
P-value (pre-post)	0.25	0.06	0.26	
HOOS-Symptoms				
Pre	37.1 ± 11	60 ± 15.9	50 ± 11.9	0.007
Post	64.2 ± 24.8	76.9 ± 17.5	60 ± 25	0.13
Change	25 ± 28.9	19.2 ± 16.7	10 ± 17	0.45
P-value (pre-post)	0.09	0.04	0.2	
HOOS-pain				
Pre	49.3 ± 15	67.7 ± 16.7	49.2 ± 20.1	0.04
Post	71 ± 21.4	83.7 ± 17.8	72.5 ± 17	0.18
Change	16 ± 15	18 ± 15	21.7 ± 17	0.86
P-value (pre-post)	0.08	0.04	0.05	
HOOS-QoL				
Pre	9.8 ± 6	30 ± 20	22.9 ± 20	0.086
Post	45.9 ± 23.3	63.7 ± 27	46.7 ± 25.7	0.152
Change	34.4 ± 26.2	25.9 ± 29	18.8 ± 13.5	0.509
P-value (pre-post)	0.04	0.03	0.03	
HOOS-ADL				
Pre	56.1 ± 16	77.8 ± 17	57.8 ± 22	0.027
Post	80.9 ± 15.8	87.3 ± 13.2	76.4 ± 21.8	0.209
Change	20.1 ± 15.3	14.5 ± 9.7	16.9 ± 19.5	0.815
P-value (pre-post)	0.03	0.02	0.03	
HOOS-SRA				
Pre	30.4 ± 10	51.3 ± 22	31.9 ± 22	0.057
Post	64.6 ± 23.2	76.9 ± 22.6	62.5 ± 26	0.251
Change	32.3 ± 27.5	23.2 ± 23	22.9 ± 20.8	0.740
P-value (pre-post)	0.03	0.04	0.04	
UCLA				
Pre	6.2 ± 2	8.4 ± 2	7.7 ± 3	0.181
Post	8.8 ± 1.6	8.3 ± 1.9	7.5 ± 2.3	0.340
Change	2.2 ± 1.9	-0.3 ± 2.3	0 ± 2	0.118
P-value (pre-post)	0.07	0.6	0.7	

Table IV. Reoperations and conversion rate to THR in the three surgical groups

	Labral reconstruction (8 hips)	Labral repair (24 hips)	Labral debridement (24 hips)	P-value
Revision to THR	2 (25%)	5 (21%)	3 (12.5%)	0.64
Mean time to THR (years)	4.1 ± 1.7	8 ± 3.9	10.3 ± 5.7	0.15
Reoperations (Screws-removal)	3 (37.5%)	13 (54%)	5 (21%)	0.06

resection group ($P = 0.036$). However, it is important to remember that in our study there was no labral resection (excision) but only a limited debridement of the damaged part of the labrum. The conclusions to be drawn from these two studies are probably that labral resection is a procedure to be avoided because it greatly compromises the future of the hip by removing all the biomechanical benefits of the labrum.

Domb *et al.* [12] compared the 5 years outcome of arthroscopic labral repair versus reconstruction, and reports similar PROMs improvement and hip joint survival in both groups, although patient satisfaction was lower in the reconstruction group. White *et al.* [15] compared primary labral reconstruction versus repair with a short follow-up of 40 months. They report 31% more failure (as defined by reoperation) with labral repair. We did not find this same difference in our study, and for us, labral repair remains the gold standard when there is a reparable tear on a viable labrum as supported by excellent outcomes at short-, mid- and long-term follow-up [4, 39–41].

The limitations of this study are the retrospective and non-randomized nature. We also analyzed patients undergoing hip surgical dislocation only as it was historically our technique of FAI surgery, and we have now moved forward to a pure arthroscopic technique. The strengths of this study are the long follow-up (10 years), the use of multiple validated hip outcomes scores, such as the WOMAC, HOOS, SF12 mental and physical and UCLA scores, and the inclusion of a match-pair analysis comparing three types of labral treatment, allowing a comparison without bias like gender, age and BMI.

CONCLUSION

Our results are reassuring regarding the long-term maintenance of clinical improvement in patients undergoing labrum reconstruction with the ligamentum teres. When compared to a match-pair group of labral repair and debridement, it provides similar survival with conversion to a THR as an endpoint, as well as similar improvement in PROMs. Labral treatment can be safely adapted at the nature of the labral lesion with a treatment 'à la carte'.

DATA AVAILABILITY

The de-identified participant data that support the findings of this study may be made available on request from the corresponding author P.E.B.

ACKNOWLEDGEMENT

None declared.

FUNDING

Zimmer Biomet Inc.

CONFLICT OF INTEREST STATEMENT

None declared.

AUTHORS' CONTRIBUTIONS

P.L.: design, data acquisition, statistical analysis, interpretation of data, writing and revision of the manuscript. P.G.: data acquisition, writing and revision of the manuscript. C.K.: data acquisition, writing and revision of the manuscript. P.B.: design, interpretation of data, supervision, writing and revision of the manuscript. All authors have reviewed and approved the written version of the manuscript.

ETHICS APPROVAL

This retrospective study involving human participants was in accordance with the ethical standards of the institutional and national research committee and with the 1964 Helsinki Declaration and its later amendments or comparable ethical standards. The study was approved by the Ottawa Health Science Network Research Ethics Board (No. 20210355-01H).

REFERENCES

1. Bsat S, Frei H, Beaulé PE. The acetabular labrum: a review of its function. *Bone Joint J* 2016; **98-B**: 730–5.
2. Cadet ER, Chan AK, Vorys GC *et al.* Investigation of the preservation of the fluid seal effect in the repaired, partially resected, and reconstructed acetabular labrum in a cadaveric hip model. *Am J Sports Med* 2012; **40**: 2218–23.
3. Greaves LL, Gilbert MK, Yung AC *et al.* Effect of acetabular labral tears, repair and resection on hip cartilage strain: a 7T MR study. *J Biomech* 2010; **43**: 858–63.
4. Byrd JWT, Jones KS. Hip arthroscopy for labral pathology: prospective analysis with 10-year follow-up. *Arthrosc J Arthrosc Relat Surg* 2009; **25**: 365–8.
5. Zaltz I. The biomechanical case for labral Débridement. *Clin Orthop* 2012; **470**: 3398–405.
6. Lodhia P, McConkey MO, Leith JM *et al.* Graft options in hip labral reconstruction. *Curr Rev Musculoskelet Med* 2021; **14**: 16–26.
7. Maldonado DR, Go CC, Laseter JR *et al.* Primary labral reconstruction in patients with femoroacetabular impingement, irreparable labral tears and severe acetabular chondral defects decreases the risk of conversion to total hip arthroplasty: a pair-matched study. *J Hip Preserv Surg* 2019; **6**: 214–26.
8. Walker JA, Pagnotto M, Trousdale RT *et al.* Preliminary pain and function after labral reconstruction during femoroacetabular impingement surgery. *Clin Orthop* 2012; **470**: 3414–20.
9. Lee S, Wuerz TH, Shewman E *et al.* Labral reconstruction with iliotibial band autografts and semitendinosus allografts improves hip joint contact area and contact pressure: an in vitro analysis. *Am J Sports Med* 2015; **43**: 98–104.

10. Nepple JJ, Philippon MJ, Campbell KJ *et al.* The hip fluid seal—Part II: the effect of an acetabular labral tear, repair, resection, and reconstruction on hip stability to distraction. *Knee Surg Sports Traumatol Arthrosc* 2014; **22**: 730–6.
11. Domb BG, El Bitar YF, Stake CE *et al.* Arthroscopic labral reconstruction is superior to segmental resection for irreparable labral tears in the hip: a matched-pair controlled study with minimum 2-year follow-up. *Am J Sports Med* 2014; **42**: 122–30.
12. Domb BG, Battaglia MR, Perets I *et al.* Minimum 5-year outcomes of arthroscopic hip labral reconstruction with nested matched-pair benchmarking against a labral repair control group. *Am J Sports Med* 2019; **47**: 2045–55.
13. Matsuda DK, Burchette RJ. Arthroscopic hip labral reconstruction with a gracilis autograft versus labral refixation: 2-year minimum outcomes. *Am J Sports Med* 2013; **41**: 980–7.
14. Scanaliato JP, Christensen DL, Salfiti C *et al.* Primary circumferential acetabular labral reconstruction: achieving outcomes similar to primary labral repair despite more challenging patient characteristics. *Am J Sports Med* 2018; **46**: 2079–88.
15. White BJ, Patterson J, Herzog MM. Bilateral hip arthroscopy: direct comparison of primary acetabular labral repair and primary acetabular labral reconstruction. *Arthrosc J Arthrosc Relat Surg* 2018; **34**: 433–40.
16. Crawford MJ, Dy CJ, Alexander JW *et al.* The 2007 frank stinchfield award. The biomechanics of the hip labrum and the stability of the hip. *Clin Orthop* 2007; **465**: 16–22.
17. Smith MV, Panchal HB, Ruberte Thiele RA *et al.* Effect of acetabular labrum tears on hip stability and labral strain in a joint compression model. *Am J Sports Med* 2011; **39 Suppl**: 103S–10S.
18. Ferguson SJ, Bryant JT, Ganz R *et al.* An in vitro investigation of the acetabular labral seal in hip joint mechanics. *J Biomech* 2003; **36**: 171–8.
19. Hanson JA, Kapron AL, Swenson KM *et al.* Discrepancies in measuring acetabular coverage: revisiting the anterior and lateral center edge angles. *J Hip Preserv Surg* 2015; **2**: 280–6.
20. Allen D, Beaulé PE, Ramadan O *et al.* Prevalence of associated deformities and hip pain in patients with cam-type femoroacetabular impingement. *J Bone Joint Surg Br* 2009; **91**: 589–94.
21. Barton C, Salineros MJ, Rakhra KS *et al.* Validity of the alpha angle measurement on plain radiographs in the evaluation of cam-type femoroacetabular impingement. *Clin Orthop* 2011; **469**: 464–9.
22. Ganz R, Gill TJ, Gautier E *et al.* Surgical dislocation of the adult hip a technique with full access to the femoral head and acetabulum without the risk of avascular necrosis. *J Bone Joint Surg Br* 2001; **83**: 1119–24.
23. Busse J, Gasteiger W, Tönnis D. A new method for roentgenologic evaluation of the hip joint—the hip factor. *Arch Orthop Unfallchir* 1972; **72**: 1–9.
24. Sierra RJ, Trousdale RT. Labral reconstruction using the ligamentum teres capitis: report of a new technique. *Clin Orthop* 2009; **467**: 753–9.
25. Beck M, Kalthor M, Leunig M *et al.* Hip morphology influences the pattern of damage to the acetabular cartilage: femoroacetabular impingement as a cause of early osteoarthritis of the hip. *J Bone Joint Surg Br* 2005; **87**: 1012–8.
26. Ware J, Kosinski M, Keller SD. A 12-item short-form health survey: construction of scales and preliminary tests of reliability and validity. *Med Care* 1996; **34**: 220–33.
27. Bellamy N, Buchanan WW, Goldsmith CH *et al.* Validation study of WOMAC: a health status instrument for measuring clinically important patient relevant outcomes to antirheumatic drug therapy in patients with osteoarthritis of the hip or knee. *J Rheumatol* 1988; **15**: 1833–40.
28. Nilsdotter AK, Lohmander LS, Klässbo M *et al.* Hip disability and osteoarthritis outcome score (HOOS) – validity and responsiveness in total hip replacement. *BMC Musculoskelet Disord* 2003; **4**: 10.
29. Zahiri CA, Schmalzried TP, Szuszczewicz ES *et al.* Assessing activity in joint replacement patients. *J Arthroplasty* 1998; **13**: 890–5.
30. Brückl R, Hepp WR, Tönnis D. Eine Abgrenzung normaler und dysplastischer jugendlicher Hüftgelenke durch den Hüftwert. *Arch Für Orthop Unf-Chir Mit Bes Berücksicht Frakturenlehre Orthop-Chir Tech* 1972; **74**: 13–32.
31. Beaulé PE, Allen DJ, Clohisey JC *et al.* The young adult with hip impingement: deciding on the optimal intervention. *J Bone Joint Surg Am* 2009; **91**: 210–21.
32. Larson CM, Giveans MR, Stone RM. Arthroscopic debridement versus refixation of the acetabular labrum associated with femoroacetabular impingement: mean 3.5-year follow-up. *Am J Sports Med* 2012; **40**: 1015–21.
33. Espinosa N, Rothenfluh DA, Beck M *et al.* Treatment of femoroacetabular impingement: preliminary results of labral refixation. *J Bone Joint Surg Am* 2006; **88**: 925–35.
34. Camenzind RS, Steurer-Dober I, Beck M. Clinical and radiographical results of labral reconstruction. *J Hip Preserv Surg* 2015; **2**: 401–9.
35. Amar E, Sampson TG, Sharfman ZT *et al.* Acetabular labral reconstruction using the indirect head of the rectus femoris tendon significantly improves patient reported outcomes. *Knee Surg Sports Traumatol Arthrosc* 2018; **26**: 2512–8.
36. Philippon MJ, Arner JW, Crawford MD *et al.* Acetabular labral reconstruction with iliotibial band autograft: outcome and survivorship at a minimum 10-year follow-up. *Jbjs* 2020; **102**: 1581–7.
37. Domb BG, Kyin C, Rosinsky PJ *et al.* Circumferential labral reconstruction for irreparable labral tears in the primary setting: minimum 2-year outcomes with a nested matched-pair labral repair control group. *Arthrosc J Arthrosc Relat Surg Off Publ Arthrosc Assoc N Am Int Arthrosc Assoc* 2020; **36**: 2583–97.
38. Schilders E, Dimitrakopoulou A, Bismil Q *et al.* Arthroscopic treatment of labral tears in femoroacetabular impingement: a comparative study of refixation and resection with a minimum two-year follow-up. *J Bone Joint Surg Br* 2011; **93**: 1027–32.
39. Domb BG, Hartigan DE, Perets I. Decision making for labral treatment in the hip: repair versus débridement versus reconstruction. *J Am Acad Orthop Surg* 2017; **25**: e53–62.
40. Hevesi M, Krych AJ, Johnson NR *et al.* Multicenter analysis of midterm clinical outcomes of arthroscopic labral repair in the hip: minimum 5-year follow-up. *Am J Sports Med* 2018; **46**: 280–7.
41. Menge TJ, Briggs KK, Dornan GJ *et al.* Survivorship and outcomes 10 years following hip arthroscopy for femoroacetabular impingement: labral debridement compared with labral repair. *J Bone Joint Surg Am* 2017; **99**: 997–1004.